

Available online at [www.sciencedirect.com](http://www.sciencedirect.com)

ScienceDirect

journal homepage: [www.JournalofSurgicalResearch.com](http://www.JournalofSurgicalResearch.com)

# The neuronal protective effects of local brain cooling at the craniectomy site after lateral fluid percussion injury in a rat model

Che-Chuan Wang, MD,<sup>a,b,c,d</sup> Yuan-Shen Chen, MD,<sup>e</sup> Bor-Shyh Lin, PhD,<sup>f</sup> Chung-Ching Chio, MD,<sup>a</sup> Chiao-Ya Hu, BD,<sup>b</sup> and Jinn-Rung Kuo, MD, PhD<sup>a,b,g,\*</sup>

<sup>a</sup>Department of Neurosurgery, Chi-Mei Medical Center, Tainan, Taiwan

<sup>b</sup>Department of Medical Research, Chi-Mei Medical Center, Tainan, Taiwan

<sup>c</sup>Institute of Photonic system, National Chiao-Tung University, Tainan, Taiwan

<sup>d</sup>Department of Child Care, Southern Taiwan University of Science and Technology, Tainan, Taiwan

<sup>e</sup>Department of Neurosurgery, National Taiwan University Hospital Yun-Lin Branch, Yunlin, Taiwan

<sup>f</sup>Institute of Imaging and Biomedical Photonics, National Chiao-Tung University, Tainan, Taiwan

<sup>g</sup>Department of Biotechnology, Southern Taiwan University of Science and Technology, Tainan, Taiwan

## ARTICLE INFO

### Article history:

Received 29 April 2013

Received in revised form

8 June 2013

Accepted 2 July 2013

Available online 26 July 2013

### Keywords:

Fluid percussion injury

Local cooling

Craniectomy

Brain temperature

Cell apoptosis

Infarction volume

Maximal angle

## ABSTRACT

**Background:** The aim of the present study is to investigate whether local brain cooling at the craniectomy site causes attenuation of traumatic brain injury (TBI) induced by fluid percussion injury (FPI).

**Methods:** Anesthetized male Sprague–Dawley rats were divided into two major treatment groups. Immediately after the onset of fluid percussion TBI, a craniectomy window of 6 × 8 mm was made at the right parietal, and a cold water bag (0°C–1°C or 5°C–6°C) was applied locally for 30 min. Additional groups of rats were used as craniectomy and craniectomy + FPI controls. Physiological parameters, such as brain and colonic temperature, mean arterial pressure, and heart rate, were monitored during FPI. Functional motor outcomes were evaluated using the inclined plane test (maximal grasp angle). Cellular infarction volume was calculated using triphenyltetrazolium chloride staining. Apoptosis and neuronal marker–positive cells in the cortex were measured by immunofluorescence staining. All functional and morphologic parameters were assessed 72 h after injury.

**Results:** Compared with the craniectomy + FPI control groups, the groups treated with 5°C–6°C local cold water therapy showed significant attenuation of the FPI-induced motor deficits, weight loss, and cerebral infarction but no effect on colonic temperature. The FPI-induced apoptosis and neuronal loss were also significantly reduced by local cooling.

**Conclusions:** Our results suggest that local cooling with 5°C–6°C cold water therapy may ameliorate TBI in rats by reducing infarction volume, neuronal cell loss, and apoptosis, resulting in improved functional outcome. We propose that the use of local cooling at the craniectomy site after FPI might have clinical benefits in the future.

© 2013 Elsevier Inc. All rights reserved.

\* Corresponding author. Department of Neurosurgery, Chi-Mei Medical Center, 901 Chung Hwa Road, Yung Kang City, Tainan, Taiwan. Tel.: +886 6 281 2811; fax: +886 6 282 8928.

E-mail address: [kuojinnrunc@gmail.com](mailto:kuojinnrunc@gmail.com) (J.-R. Kuo).  
0022-4804/\$ – see front matter © 2013 Elsevier Inc. All rights reserved.  
<http://dx.doi.org/10.1016/j.jss.2013.07.002>

Group	Parameters (n = 6)						
	MAP HR	Brain colon temperature	TTC staining	TUNEL staining	NeuN plus DAPI staining	Body weight loss	Motor maximum angle
Craniectomy	−10 to 80 min after craniectomy	−10 to 80 min after craniectomy	72 h after craniectomy	72 h after craniectomy	72 h after craniectomy	72 h after craniectomy	72 h after craniectomy
FPI + craniectomy	−10 to 80 min after FPI	−10 to 80 min after FPI	72 h after FPI	72 h after FPI	72 h after FPI	72 h after FPI	72 h after FPI
FPI + craniectomy + 0°C–1°C cooling 30 min	−10 to 80 min after FPI	−10 to 80 min after FPI	72 h after FPI	72 h after FPI	72 h after FPI	72 h after FPI	72 h after FPI
FPI + craniectomy + 5°C–6°C cooling 30 min	−10 to 80 min after FPI	−10 to 80 min after FPI	72 h after FPI	72 h after FPI	72 h after FPI	72 hrs after FPI	72 h after FPI
DAPI = 4',6'-diamidino-2-phenylindole.							

a 12-h light-to-dark cycle and allowed free access to food and water. All experimental procedures were approved by the Animal Research Committee of the Chi-Mei Medical Center. These procedures were performed in compliance with the regulations of the National Institutes of Health for the use of animals in research to minimize discomfort in the animals during surgery and recovery. At the end of the experiments, the control and other rats that survived TBI were sacrificed with an overdose of urethane.

### 2.3. TBI

The animals were anesthetized with an intraperitoneal administration of sodium pentobarbital (50 mg/kg), ketamine (intramuscularly [IM], 44 mg/kg), Xylazine hydrochloride (Rompun) (IM, 6.77 mg/kg), and atropine (IM, 0.026 mg/kg). A craniectomy 2 mm in radius, 4 mm from bregma, and 3 mm from sagittal sutures over the right parietal cortex was performed via stereotaxic frame. After the craniectomy and implantation of injury cannula, the fluid percussion device was connected to the animal via the Luer-lock fitting, and the brain was injured with a 25-ms percussion of 2.0–2.2 atm. This produces a moderate-severity brain trauma as originally described by McIntosh *et al.* [18]. A transient hypertensive response, apnea, and seizure were observed immediately after fluid percussion injury (FPI), and this combination was used as the inclusion criterion for successful FPI. The animals were then separated into FPI + craniectomy or FPI + craniectomy + LBCCS groups.

### 2.4. Surgery and physiological parameter monitoring

The rats' right femoral artery was cannulated with polyethylene tubing under sodium pentobarbital anesthesia for blood pressure monitoring. All recordings were made on a four-channel Gould polygraph. The rats' core temperatures were monitored continuously using a thermocouple, and the mean arterial pressure (MAP) and heart rate (HR) were continuously monitored using a pressure transducer. Frontal cortex brain temperature was monitored using a digital electric thermometer (model DP80; Omega Engineering, Inc, Stamford, CT) with a 0.15-mm-diameter temperature probe (model YP-033-1-T-G-60-SMP-M; Omega Engineering, Inc) inserted 4.0 mm ventral to the surface of the skull. The probe was removed before FPI and replaced immediately after injury. Colon temperatures were measured with an analog electronic thermometer (model 43 TE; YSI, Inc, Yellow Springs, OH) and temperature probe (series 400; YSI, Inc).

### 2.5. Experimental groups

The animals were randomly assigned to craniectomy, FPI plus brain craniectomy, FPI plus brain craniectomy and local cooling with 5°C–6°C of cold water, and the FPI plus brain craniectomy and local cooling with 0°C–1°C of cold water groups. All tests were blinded, and the animal codes were revealed only at the end of the analyses. The animals were treated with local cooling after the craniectomy procedure was completed (15 min after FPI), and they then received local

cooling for 30 min. The craniectomy window was of 1-mm size and located 7 mm from bregma and 3 mm and 8 mm from sagittal sutures in the right parietal cortex; the craniectomy was performed via stereotaxic frame. The cold water temperature was monitored using an analog electronic thermometer (model 43 TE; YSI, Inc) and temperature probe (series 400; YSI, Inc). For testing the safety of local cooling therapy, two groups, including craniectomy + local cooling with 0°C–1°C and 5°C–6°C of cold water, were assigned.

### 2.6. Cerebral infarction assay

Infarct volume was assessed using 2,3,5-triphenyltetrazolium chloride (TTC; Sigma, St Louis, MO) staining as demonstrated previously [19]. All animals were sacrificed 3 d after injury. The brain slices, in 2-mm sections, were incubated in 2% TTC dissolved in phosphate-buffered saline (PBS) for 30 min at 37°C and then transferred to a 5% formaldehyde solution for fixation. The volume of infarction, as revealed by negative TTC stains (pale color), was measured in each slice and summed using computerized planimetry (personal computer–based Image Tools software; Media Cybernetics, Inc). The infarction volume was calculated as 2 mm (slice thickness) × (sum of the infarction area in all brain slices [mm<sup>2</sup>]).

#### 2.6.1. Cell apoptotic assay

Three days after injury, apoptotic cells were identified by staining with terminal deoxynucleotidyl transferase–mediated deoxyuridine triphosphate–biotin nick end labeling (TUNEL) [20] using previously described procedure [21]. The number of TUNEL-positive cells was calculated in five coronal sections from each rat in the samples and summed using computerized planimetry (personal computer–based Image Tools software). The following antibodies were used in this study: monoclonal mouse anti–neuronal-specific nuclear protein (NeuN, MAB377; Chemicon Millipore Corporation, Billerica, MA) and Alexa Fluor 568 anti-mouse IgG (A11031; Life Technologies Co, Grand Island, NY).

#### 2.6.2. Neuronal loss in cortex

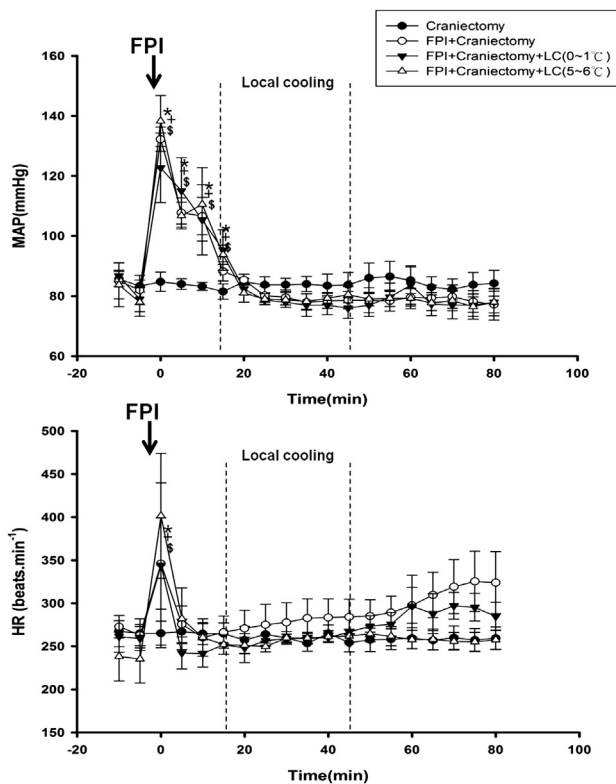
Adjacent 50-μm sections corresponding to coronal coordinates 0.20–0.70 mm anterior to bregma were incubated in 2 mol/L of HCl for 30 min, rinsed in 0.1 mol/L of boric acid (pH 8.5) for 3 min at room temperature, and then incubated with primary antibodies in PBS containing 0.5% normal bovine serum at 4°C overnight. After being washed in PBS, the sections were incubated with secondary antibodies for 1 h at room temperature. The following antibodies were used in this study: mouse anti-NeuN at 1:200 dilution and Alexa Fluor 568 goat anti-mouse IgG. The sections were then washed in PBS with 0.6% Triton X-100, incubated with fluorescein isothiocyanate-conjugated anti-rabbit IgG in 1% bovine serum albumin/PBS/0.1% Triton X-100 for 60 min, and mounted with anti-fade mounting media. The number of labeled cells was calculated in five coronal sections from each rat and expressed as the mean number of cells per section. For negative control sections, all procedures were performed in the same manner without the primary antibodies.

## 2.7. Functional outcome

An inclined plane was used to measure limb strength. The animals were placed facing right and then left, perpendicular to the slope of a 20 × 20 cm rubber ribbed surface of the inclined plane starting at an angle of 55° [22]. The angle was increased or decreased in five increments to determine the maximal angle at which an animal could hold onto the plane. The measurement for each day was the mean of the left- and right-side maximal angles.

## 2.8. Statistical analysis

Immunoreactive cell count and lesion volumes were evaluated for Gaussian (normal) distribution and expressed as means ± standard errors of the mean. The data were analyzed with one-way analysis of variance and if  $P < 0.05$ , analyzed using a Newman–Keuls *post hoc* test. Differences were considered to be statistically significant when  $P < 0.05$ . All data were analyzed with SigmaPlot, version 11.0, for Windows (Systat Software, San Jose, CA).



**Fig. 1** – The effects of local cooling treatment on MAP and HR after FPI. All FPI groups showed a transient significant increase in MAP and HR. MAP and HR also showed no lasting significant differences between the groups during the local cooling treatment. \* $P < 0.05$ , FPI + craniectomy + local cooling (5°C–6°C) group compared with the craniectomy group ( $n = 6$ ); + $P < 0.05$ , FPI + craniectomy + local cooling (0°C–1°C) group compared with the craniectomy group ( $n = 6$ ); \$ $P < 0.05$ , FPI + craniectomy + local cooling group compared with the craniectomy group ( $n = 6$ ). LC = local cooling.

## 3. Results

### 3.1. Acute effects of FPI

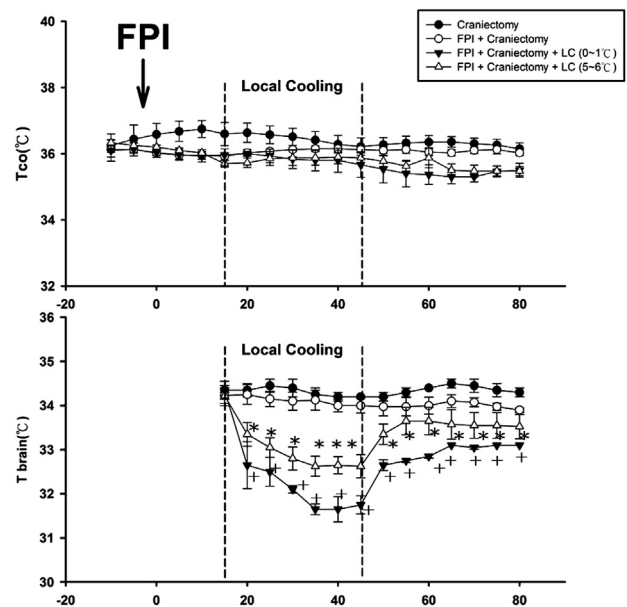
The average impact intensity of the fluid pulse delivered to animals in the injured group was  $2.09 \pm 0.02$  atm (mean ± standard error of the mean), and the impact time was  $0.0246 \pm 0.0004$  s. Immediately after this impact, all rats experienced a transient of apnea ( $38.8 \pm 9.0$  s), hypertension (up to approximately 140 mm Hg), and tachycardia (approximately 400 beats/min). Craniectomy control animals showed no apnea, hypertension, or tachycardia. There was no difference between the two treatment groups.

### 3.2. LBCCS affected neither MAP nor HR after FPI

The craniectomy + local cooling (0°C–1°C and 5°C–6°C) with cold water groups showed decreased MAP, HR, and colon temperature within an 80-min timecourse, but these effects were not significant (Fig. 1).

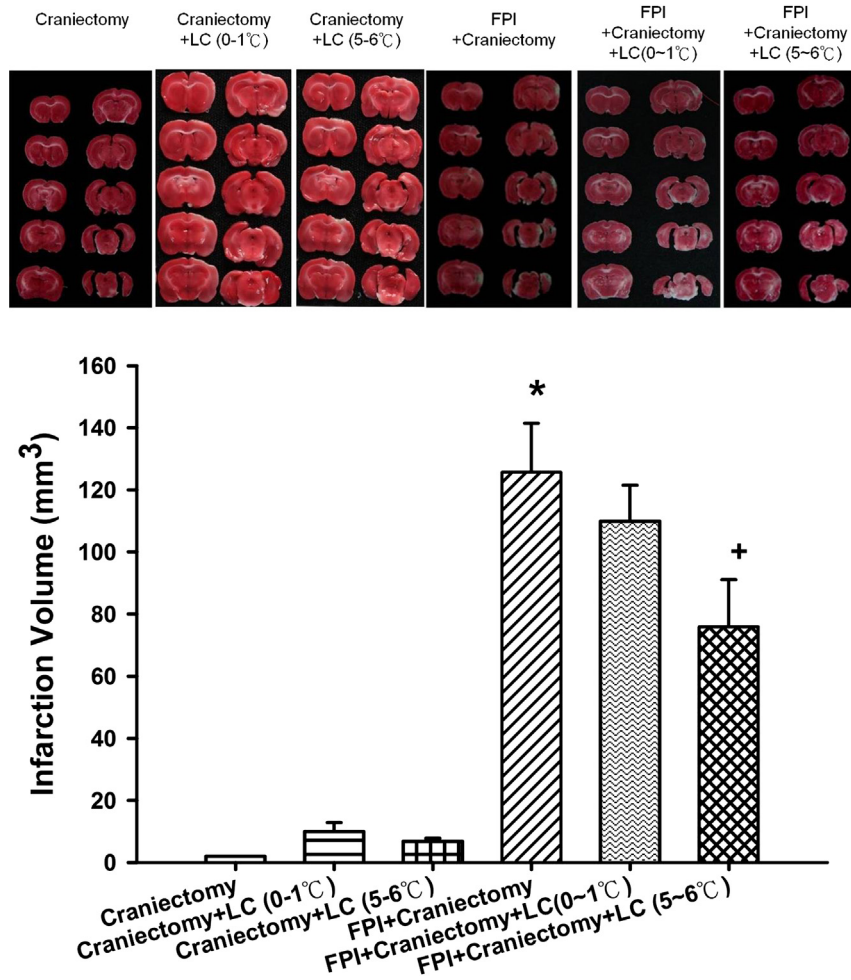
### 3.3. LBCCS significantly decreased brain temperature but not rectal temperature

The craniectomy + FPI group maintained their rectal temperature and insignificantly decreased their brain



**Fig. 2** – The effects of local cooling treatment on brain and rectal temperatures. Without interfering with the rectal temperature, craniectomy plus FPI and cold water (0°C–1°C and 5°C–6°C)–treated groups showed significantly decreased brain temperatures over an 80-min timecourse. \* $P < 0.05$ , FPI + craniectomy + local cooling (5°C–6°C) group compared with the FPI + craniectomy group ( $n = 6$ ); + $P < 0.05$ , FPI + craniectomy + local cooling (0°C–1°C) group compared with the FPI + craniectomy group ( $n = 6$ ). LC = local cooling.





**Fig. 3** – The effects of local cooling on the FPI-induced infarction volume in the ischemic cortex 3 d after FPI. \* $P < 0.05$ , craniectomy group compared with the FPI + craniectomy group; + $P < 0.05$ , FPI + craniectomy group compared with the FPI + craniectomy + local cooling (5°C–6°C) group. LC = local cooling.

temperature, to 36.5°C and 34.5°C, respectively, over an 80-min timecourse. Both the craniectomy + local cooling groups showed significant decreases in brain temperature over an 80-min timecourse, with temperatures of 32.5°C–33.5°C and 31.5°C–33.0°C for the 5°C–6°C and 0°C–1°C of cold water-treated groups, respectively (Fig. 2).

### 3.4. LBCCS with 5°C–6°C of cold water significantly reduced the FPI-induced cerebral infarction volume

The TTC-stained sections, 3 d after FPI, showed a significant increase in the infarcted area in the craniectomy + FPI group compared with that in the craniectomy controls. The FPI-induced infarction volume was significantly decreased by LBCCS with 5°C–6°C of cold water treatment but not by the 0°C–1°C ice-water treatment ( $P < 0.05$ ;  $n = 6$ ; Fig. 3).

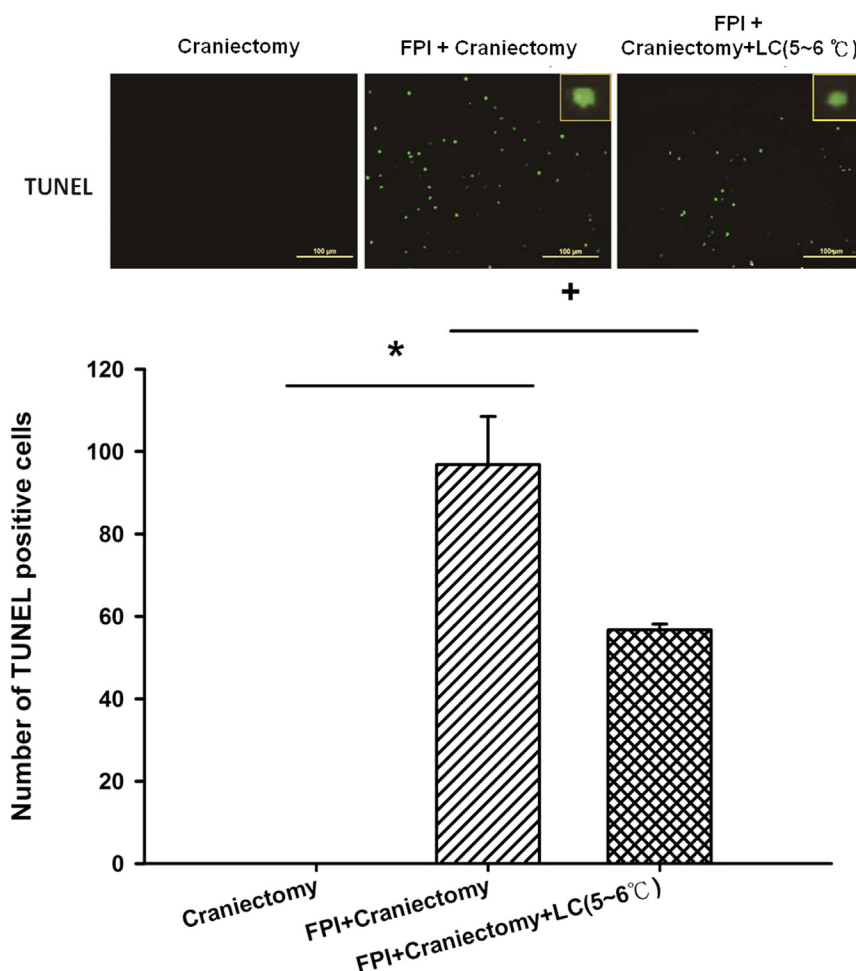
To examine the safety of local cooling, we tested the craniectomy control groups receiving LBCCS treatment with 0°C–1°C or 5°C–6°C of cold water without FPI. These results showed no significant difference in infarction volume between the 0°C–1°C and 5°C–6°C groups (Fig. 3).

### 3.5. LBCCS with 5°C–6°C of cold water significantly decreased the FPI-induced apoptosis

Based on the results of the infarction volume, we next evaluated the effect of LBCCS with 5°C–6°C of cold water on FPI-induced apoptosis, neuronal loss, body weight loss, and motor deficiency. The craniectomy + FPI group exhibited a significant increase in the number of TUNEL-positive cells in the ischemic cortex 3 d after FPI compared with the craniectomy control group ( $96.8 \pm 11.7$  versus 0;  $P < 0.01$ ,  $n = 6$ ). The craniectomy + FPI + local cooling (with 5°C–6°C of cold water) group had significantly fewer TUNEL-positive cells compared with the craniectomy + FPI group ( $56.7 \pm 1.5$  versus  $96.8 \pm 11.7$ ;  $P < 0.05$ ,  $n = 6$ ) (Fig. 4).

### 3.6. LBCCS with 5°C–6°C of cold water significantly decreased the FPI-induced neuronal loss

The craniectomy + FPI group exhibited significantly fewer NeuN-positive cells in the ischemic cortex 3 d after FPI than the craniectomy control group ( $67.3 \pm 8.1$  versus  $180.7 \pm 11.6$ ;  $P < 0.01$ ,  $n = 6$ ). The craniectomy plus FPI and local cooling



**Fig. 4 – The effects of local cooling (5°C–6°C) treatment on the FPI-induced apoptosis in ischemic cortex at 3 d after FPI.** The top panels depict representative positive TUNEL staining for one craniectomy, one FPI + craniectomy, and one FPI + craniectomy + local cooling treatment rats. \* $P < 0.05$ , craniectomy group compared with the FPI + craniectomy group; + $P < 0.05$ , FPI + craniectomy group compared with FPI + craniectomy + local cooling (5°C–6°C) group. LC = local cooling.

(5°C–6°C of cold water-treated) group had significantly more NeuN-positive cells than the craniectomy plus FPI group ( $121.0 \pm 8.7$  versus  $67.3 \pm 8.1$ ;  $P < 0.05$ ,  $n = 6$ ) (Fig. 5).

### 3.7. LBCCS with 5°C–6°C of cold water significantly decreased the FPI-induced body weight loss

The body weight loss 3 d after FPI was significantly greater than that in the craniectomy controls ( $31.5 \pm 4.2$  g versus  $52.1 \pm 2.1$  g;  $P < 0.05$ ;  $n = 6$ ). The FPI-induced body weight loss was significantly decreased by the treatment of LBCCS with 5°C–6°C of cold water after FPI ( $52.1 \pm 2.1$  g versus  $39.5 \pm 3.5$  g;  $P < 0.05$ ;  $n = 6$ ) (Fig. 6).

### 3.8. LBCCS with 5°C–6°C of cold water significantly attenuates FPI-induced motor deficits

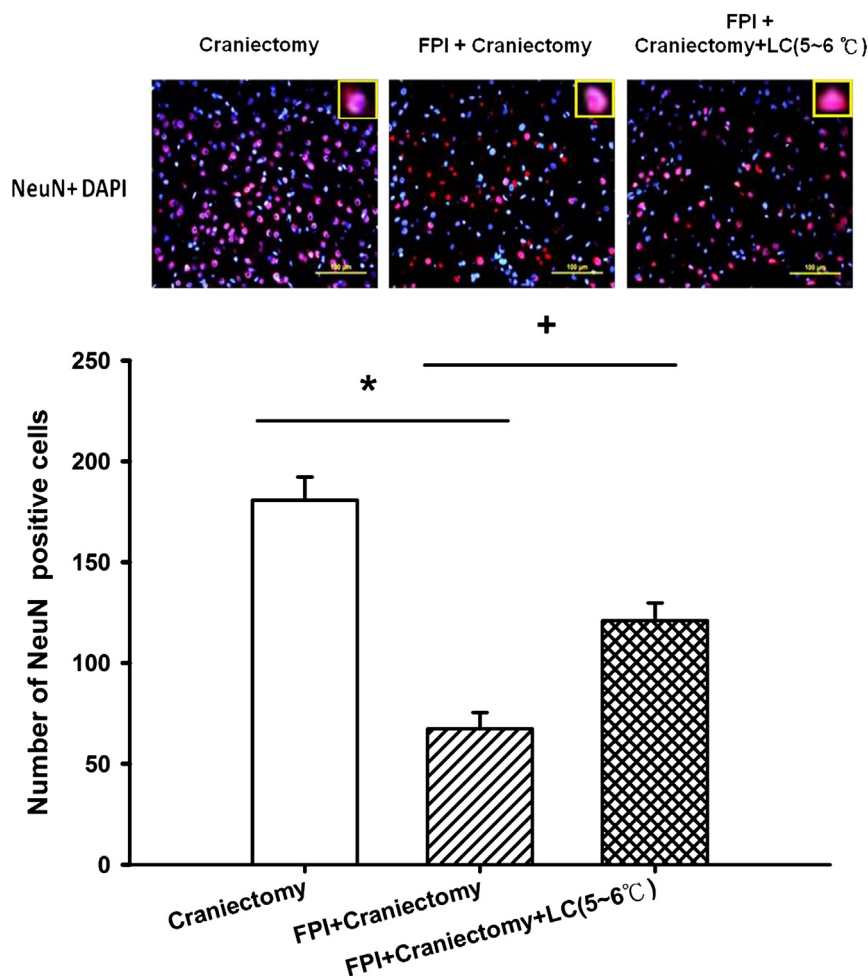
Three days after the FPI, behavioral tests revealed that rats in the craniectomy + FPI group performed significantly worse on

a motor function test than the craniectomy controls ( $54.5 \pm 1.5$  versus  $60.0 \pm 1.4$ ;  $P < 0.05$ ;  $n = 6$ ). The TBI-induced motor dysfunction was significantly reduced by LBCCS with 5°C–6°C of cold water in an ice bag ( $54.5 \pm 1.5$  versus  $59.5 \pm 0.9$ ;  $P < 0.05$ ;  $n = 6$ ) (Fig. 7).

## 4. Discussion

### 4.1. Novelty of the present study

In the present study, LBCCS with 5°C–6°C of cold water counteracted the deficits induced by TBI in rat, including infarction volume, apoptosis, neuronal survival in the ischemic cortex, and neurologic deficits, without affecting the systemic temperature or inducing systemic complications. To the best of our knowledge, this is the first study to report brain temperature profiles using local brain cooling methods in a traumatic central nervous system injury experimental



**Fig. 5** – The effects of local cooling (5°C–6°C) treatment on the FPI-induced neuronal loss in ischemic cortex at 3 d after FPI. The top panels depict representative positive NeuN and DAPI staining for one craniectomy, one FPI + craniectomy, and one FPI + craniectomy + local cooling treatment rats. \* $P < 0.05$ , craniectomy group compared with the FPI + craniectomy group; + $P < 0.05$ , FPI + craniectomy group compared with FPI + craniectomy + local cooling (5°C–6°C) group. DAPI = 4',6-diamidino-2-phenylindole; LC = local cooling.

model. These data will hopefully serve as a foundation for future studies on the LBCCS therapy for TBI.

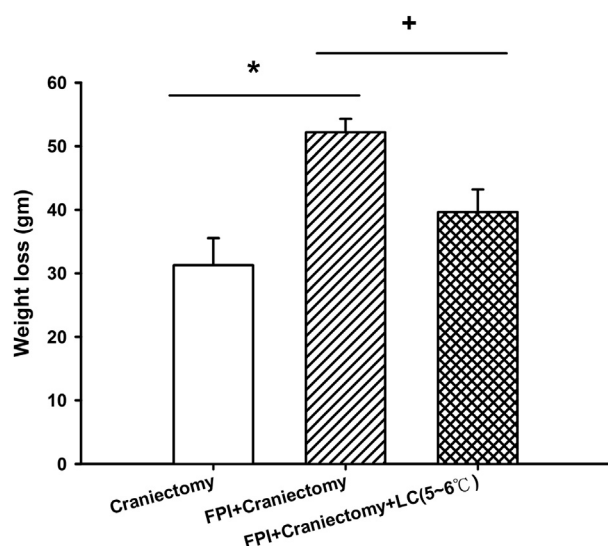
#### 4.2. Safety of the LBCCS

As the clinical implications could be very serious, the safety of selective LBCCS with 5°C–6°C of cold water should be evaluated. First, in the present study, we cooled only the damaged brain without affecting the systemic temperature. The complications of whole-body cooling, such as severe shivering, increased incidence of arterial hypotension, cardiac arrhythmia, hemorrhage, and infection [6,8], did not occur in the present study. Second, when the control animals (no FPI) were exposed to local brain cooling (5°C–6°C), although the infarction volume was small ( $7 \pm 2 \text{ mm}^3$ ), the overall LBCCS with 5°C–6°C of cold water significantly reduced FPI-induced cerebral infarction volume 3 d after FPI. We consider that LBCCS is likely to be safe at least in the short term; nevertheless, the long-term complications must be evaluated.

#### 4.3. Rationale for LBCCS

Besides the use of DC, the management guidelines for serious TBI recommended by the Asia-Oceania Neurotrauma Society include the management of ICP and cerebral perfusion pressure, as well as the use of sedatives [23].

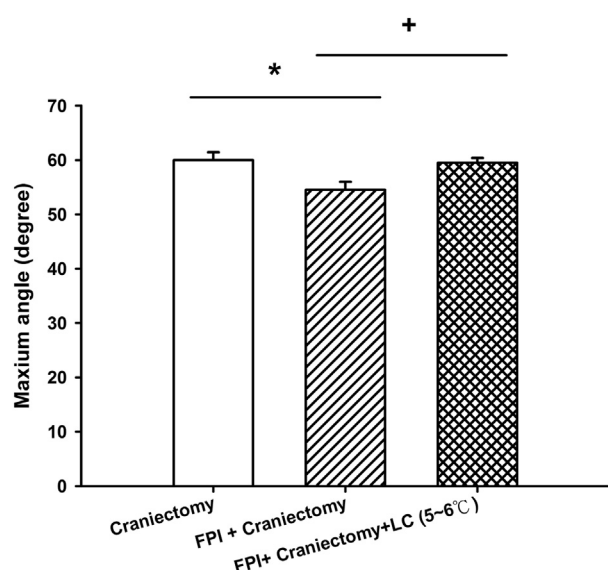
However, after TBI, most patients do not require a craniectomy. If selective brain cooling is considered, whole-brain cooling, such as retrograde jugular vein flush with 4°C saline [8,13,24] and intracarotid artery with 5°C cold solution perfusion [25], do not require this kind of surgical procedure. Cooling on the craniectomy site may have clinical limitations. However, DC has been considered to be a life-saving procedure after moderate to severe TBI [15,26]. After DC was performed, ICP has been shown to decrease and the cerebral perfusion pressure to increase, with these effects being maintained at levels that were ideal for patients [27,28]. Furthermore, the removal of skull bone and duraplasty at the brain injury site facilitates the heat transfer by conduction,



**Fig. 6 – The effects of local cooling (5°C–6°C) treatment on TBI-induced body weight loss 3 d after FPI. \* $P < 0.05$ , craniectomy group compared with the FPI + craniectomy group; + $P < 0.05$ , FPI + craniectomy group compared with FPI + craniectomy + local cooling (5°C–6°C) group. LC = local cooling.**

convention, and radiation from the brain parenchyma, allowing for more effective neuronal cooling [16]. Thus, DC in certain cases may be beneficial if it is clinically indicated.

Consistent with the study by Prandini *et al.* [29], using a middle cerebral artery occlusion animal model, in the present



**Fig. 7 – The effects of local cooling (5°C–6°C) treatment on TBI-induced motor deficits as evaluated using the maximum angle in inclined plane grasp 3 d after FPI. \* $P < 0.05$ , craniectomy group compared with the FPI + craniectomy group; + $P < 0.05$ , FPI + craniectomy group compared with FPI + craniectomy + local cooling (5°C–6°C) group. LC = local cooling.**

study, LBCCS reduced the infarction volume in an experimental rat TBI model. This result also showed that local cooling on the previously performed craniectomy site may prevent secondary brain damage when craniectomy is clinically indicated.

Compared with whole-brain cooling by retrograde jugular vein flush with 4°C saline [8,13,24], intracarotid artery with 5°C cold solution perfusion [25], and cooling cuff containing cold circulating water wrapped around the bilateral common carotid arteries [30], our LBCCS method is noninvasive, concerns less complications, and is easily performed and effective. We believe that the least invasive and most selective methods of hypothermia hold the greatest promise of becoming practical measures for providing neuroprotection after TBI.

Similar to the previous results using invasive retrograde jugular vein flush brain cooling in a rat model [8,22,31] and epidural cooling in a monkey model [32], in the present results, LBCCS with 5°C–6°C of cold water for 30 min after FPI significantly induces rapid brain cooling (5 min to 32°C and 20 min to 33.5°C for approximately 80 min) and improves outcome of severe TBI in the rat. At the same time, the systemic temperature was insignificantly changed (maintained at approximately 36°C). Thus, it appears that LBCCS specifically induces brain cooling without interfering with body temperature and would thus be safer and not require intensive care. Because local cooling is a simple procedure that is frequently used in the intensive care unit for fever control, we propose that LBCCS may be useful in clinical applications in TBI patients who have undergone DC for neuroprotection.

#### 4.4. Local brain cooling effects on neuroprotection

In the present study, consistent with previous whole-brain cooling studies (mean brain temperature of 33°C) [8,13], LBCCS with 5°C–6°C of cold water (maintaining the brain temperature at 32.5°C–33.5°C) was neuroprotective. This result was demonstrated by the preservation of neurons and the reduction of apoptosis and infarction volume after TBI. Other mechanisms of neuroprotection provided by whole-brain cooling after brain injury were reported to be by reducing brain lactate accumulation [8]; reducing brain nitrosative and oxidative damage [14]; modulating reactive astrogliosis, microgliosis, caspase 3 activation, neuronal apoptosis, and neurogenesis [13]; and attenuating systemic inflammation, activated coagulation, and tissue ischemia and injury [33]. It is likely that LBCCS with 5°C–6°C of cold water may act through similar mechanisms to improve the outcome of TBI. Based on our results, we propose that maintaining brain temperature at 32.5°C–33.5°C may be the threshold temperature required to obtain a therapeutic effect. However, this hypothesis requires verification.

Why was the LBCCS with 0°C–1°C of cold water ineffective at decreasing infarction volume and functional outcome? In the present study, the brain temperature stayed in the range of 31.5°C–33.0°C on LBCCS with 0°C–1°C of cold water. Whether cold injury using 0°C–1°C of cold water at the craniectomy site induced brain injury, such as reduction in regional cerebral blood flow, increased lactate-to-pyruvate ratio and local tissue hypoxia [34], or severe impairment of



the microcirculation and brain–blood barrier breakdown [35,36], was involved in our TBI model remains to be evaluated.

#### 4.5. Limitations of the present study

Several drawbacks of LBCCS should be considered. First, the uneven distribution of cooling to various brain regions would make LBCCS ineffective for injuries to deeper structures [37]. Second, severe TBI is often complicated by intracranial hypertension and usually involves damage to both sides of the brain rather than just the unilateral DC site. Clinically, patients who require craniectomy have extensive brain injury and edema. The injury is usually not localized to one part of the brain [4]. How effective local cooling will be in the setting of extensive systemic injury must be evaluated in the future. Therefore, further research is clearly indicated to delineate the risks and benefits associated with LBCCS therapies. Third, application of local cooling to a craniectomy site that was created immediately after the injury may have no clinical correlation. Although we have successfully demonstrated the beneficial effects of LBCCS on a TBI animal model, the therapeutic window of LBCCS must be evaluated, comparing animals craniectomized immediately after TBI or with a delay of 1, 3, or 8 h as recommended by Plesnila [38]. These concerns would suggest that the clinical applicability and effectiveness of LBCCS are premature.

## 5. Conclusions

Our results suggest that local cooling therapy with 5°C–6°C of cold water in an ice bag may ameliorate TBI in rats by reducing infarction volume, neuronal loss, and neuronal apoptosis, resulting in improvements in functional outcome and body weight loss. We also suggest that local cooling shortly after craniectomy may have clinical benefits.

## Acknowledgment

The authors thank the Chi-Mei Medical Center, Tainan, Taiwan for their instrumental support. The authors also thank Dr Kao-Chao, Lin for critical comments on the manuscript.

## REFERENCES

- [1] Nortje J, Menon DK. Traumatic brain injury: physiology, mechanism and outcome. *Curr Opin Neurol* 2004;17:711.
- [2] Bullock MR, Chesnut R, Ghajar J, et al. Guidelines for the surgical management of traumatic brain injury. *Neurosurgery* 2006;58:S16.
- [3] Ono J, Yamaura A, Kubota M, Okimura Y, Isobe K. Outcome prediction in severe head injury: analyses of clinical prognostic factors. *J Clin Neurosci* 2001;8:1203.
- [4] Ucar T, Akyuz M, Kazan S, Tuncer R. Role of decompressive surgery in the management of severe head injuries: prognostic factors and patient selection. *J Neurotrauma* 2005;22:1311.
- [5] Fay T. Observations on generalized refrigeration in cases of severe cerebral trauma. *Assoc Res Nerv Ment Dis Proc* 1943;24:611.
- [6] Gladstone DJ, Black SE, Hakim AM. Heart and Stroke Foundation of Ontario Centre of Excellence in Stroke Recovery. Toward wisdom from failure: lessons from neuroprotective stroke trials and new therapeutic directions. *Stroke* 2002;33:2123.
- [7] Krieger DW, Yenari MA. Therapeutic hypothermia for acute ischemic stroke: what do laboratory studies teach us? *Stroke* 2004;35:1482.
- [8] Chio CC, Kuo JR, Hsiao SH, Chang CP, Lin MT. Effect of brain cooling on brain ischemia and damage markers after fluid percussion brain injury in rats. *Shock* 2007;28:284.
- [9] Harris OA, Muh CR, Surlis MC, et al. Discrete cerebral hypothermia in the management of traumatic brain injury: a randomized controlled trial. *J Neurosurg* 2009;110:1256.
- [10] Andrews PJ, Harris B, Murray GD. Randomized controlled trial of effects of the airflow through the upper respiratory tract of intubated brain-injured patients on brain temperature and selective brain cooling. *Br J Anaesth* 2005;94:330.
- [11] Liu WG, Qiu WS, Zhang Y, Wang WM, Lu F, Yang XF. Effects of selective brain cooling in patients with severe traumatic brain injury: a preliminary study. *J Int Med Res* 2006;34:58.
- [12] Christian E, Zada G, Sung G, Giannotta SL. A review of selective hypothermia in the management of traumatic brain injury. *Neurosurg Focus* 2008;25:E9.
- [13] Kuo JR, Lo CJ, Chang CP, Lin MT, Chio CC. Brain cooling—stimulated angiogenesis and neurogenesis attenuated traumatic brain injury in rats. *J Trauma* 2010;69:1467.
- [14] Kuo JR, Lo CJ, Chang CP, Lin MT, Chio CC. Attenuation of brain nitrostatic and oxidative damage by brain cooling during experimental traumatic brain injury. *J Biomed Biotechnol* 2011;2011:145214.
- [15] Kuo JR, Lo CJ, Lu CL, Chio CC, Wang CC, Lin KC. Prognostic predictors of outcome in an operative series in traumatic brain injury patients. *J Formos Med Assoc* 2011;110:258.
- [16] Forte LV, Peluso CM, Prandini MN, Godov R, Roias SS. Regional cooling for reducing brain temperature and intracranial pressure. *Arq Neuropsiquiat* 2009;67:480.
- [17] Pierce JE, Smith DH, Trojanowski JQ, McIntosh TK. Enduring cognitive, neurobehavioral and histopathological changes persist for up to one year following severe experimental brain injury in rats. *Neuroscience* 1998;87:359.
- [18] McIntosh TK, Vink R, Noble L, et al. Traumatic brain injury in the rat: characterization of a lateral fluid-percussion model. *Neuroscience* 1989;28:233.
- [19] Kuo JR, Lo CJ, Chio CC, Chang CP, Lin MT. Resuscitation from experimental traumatic brain injury by agmatine therapy. *Resuscitation* 2007;75:506.
- [20] Mullen RJ, Buck CR, Smith AM. NeuN, a neuronal specific nuclear protein in vertebrates. *Development* 1992;116:201.
- [21] Chuang TJ, Lin KC, Chio CC, Wang CC, Chang CP, Kuo JR. Effects of secretome obtained from normoxia-preconditioned human encephalal stem cells in traumatic brain injury rats. *Trauma Acute Care Surg* 2012;73:1161.
- [22] Hallam TM, Floyd CL, Folkerts MM, et al. Comparison of behavioral deficits and acute neuronal degeneration in rat lateral fluid percussion and weight-drop brain injury models. *J Neurotrauma* 2004;21:521.
- [23] Chiu WT, Liao KH, Shigemori M, Cho KS, Jiang JY, Lin JW. Novel consensus of management guidelines for severe traumatic brain injury in Asia. *J Neurotrauma* 2010;27:775.

- [24] Wen YS, Huang MS, Lin MT, Lee CH. Rapid brain cooling by hypothermic retrograde jugular vein flush. *J Trauma* 2005;58:577.
- [25] Jiang JY, Xu W, Yang PF, Gao GY, Gao YG, Liang YM. Marked protection by selective cerebral profound hypothermia after complete cerebral ischemia in primates. *J Neurotrauma* 2006; 23:1847.
- [26] Skoglund TS, Eriksson-Ritzen C, Jensen C, Rydenhag B. Aspects on decompressive craniectomy in patients with traumatic head injury. *J Trauma* 2006;3:1502.
- [27] Kuo JR, Yeh TC, Sung KC, Wang CC, Chen CW, Chio CC. Intraoperative applications of intracranial pressure monitoring in patients with severe head injury. *J Clin Neurosci* 2006;13:218.
- [28] Schneider GH, Bardt T, Lanksch WR, Unterberg A. Decompressive craniectomy following traumatic brain injury: ICP, CPP and neurologic outcome. *Acta Neurochir Suppl* 2002;81:77.
- [29] Prandini M, Lacanns S, Valente P, Stavale J. Regional mild hypothermia in the protection of ischemic brain. *Acta Cir Bras* 2002;17:232.
- [30] Wei G, Hartings JA, Yang X, Tortella FC, Lu XC. Extraluminal cooling of bilateral common carotid arteries as a method to achieve selective brain cooling for neuroprotection. *J Neurotrauma* 2008;25:549.
- [31] Wen YS, Huang MS, Lin MT, Lee CH. Hypothermic retrograde jugular perfusion reduces brain damage in rats with heatstroke. *Crit Care Med* 2003;31:2641.
- [32] King C, Robinson T, Dixon CE, Rao GR, Larnard D, Nemoto CE. Brain temperature profiles during epidural cooling with the ChillerPad in a monkey model of traumatic brain injury. *J Neurotrauma* 2010;27:1895.
- [33] Hsu SF, Niu KC, Lin CL, Lin MT. Brain cooling causes attenuation of cerebral oxidative stress, systemic inflammation, activated coagulation, and tissue ischemia/injury during heatstroke. *Shock* 2006; 20:210.
- [34] Frei HJ, Wallenfang TH, Poll W, Reulen HJ, Schubert R, Brock M. Regional cerebral blood flow and regional metabolism in cold induced edema. *Acta Neurochirurgica* 1973;29:15.
- [35] Kuchiwaki H, Inao S, Nagasaka M, Andoh K, Hirano T, Sugita K. The effects of cerebral haemodynamics on the progression of cold-induced edema. *Acta Neurochir Suppl (Wien)* 1990;51:77.
- [36] Murakami K, Kondo T, Yang G, Chen SF, Morita-Fujimura Y, Chan PH. Cold injury in mice: a model to study mechanisms of brain edema and neuronal apoptosis. *Prog Neurobiol* 1999; 57:289.
- [37] Cheng H, Shi J, Zhang L, Zhang Q, Yin H, Wang L. Epidural cooling for selective brain hypothermia in porcine model. *Acta Neurochir (Wien)* 2006;148:559.
- [38] Plesnila N. Decompression craniectomy after traumatic brain injury: recent experimental results. *Prog Brain Res* 2007; 161:393.